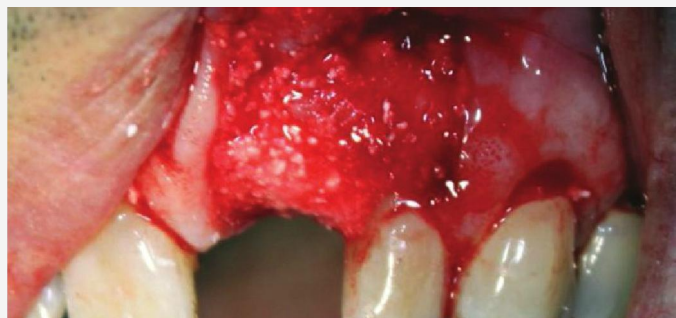

32

News No. 32 May 2013

Using BONDBONE® as a composite in post extraction sockets with immediate implant placement – everyday practice.



mis[®]
MAKE IT SIMPLE

Using BONDBONE® as a composite in post extraction sockets with immediate implant placement – everyday practice.

Miguel de Melo Costa, DMD¹.

Introduction

Treatment time is more than ever a factor to consider when rehabilitating our patients. Although biology plays an important role, there are more and more reliable techniques that allow us to obtain great results in a shorter period of time.

The immediate placement of implants in post-extraction sockets is a routine procedure used for many years, widely described and with several advantages during both surgery and the prosthetic rehabilitation^{1,2,3}. Whether it is done with or without simultaneous restoration, it has the following main advantages:

- Preservation of the contour and form of the soft tissues.
- Decrease of the period of edentulism.
- Predictability.
- Esthetically more pleasing restorations.
- Decrease of the number of surgeries.
- Decrease of the treatment's morbidity.
- Decrease of the treatment's cost.

Araújo^{4,5,6} demonstrated that the loss of bone was independent of the placement (or not) of immediate implants and was linked to the bundle bone. As such, this factor also has to be taken into consideration. The buccal bone position and thickness as well as postextraction remodeling have to be considered both in the correct placement of the implants and in the use of bone grafts, in order to avoid esthetic problems.

In some cases, the biggest clinical difficulty is to decide which type of procedure should be used. In these situations the classification of Juodzbaly and Wang⁷ that assesses parameters such as soft tissues (quantity, quality

and biotype), hard tissues (vertical position, thickness of the buccal bone and height of the interproximal bone), the interproximal distance between adjoining teeth and the need for implants in a specific angle position helps making a decision tree.

In both cases we made adjustments to the classification because in our opinion these bone defects were more favorable than those in the classification. They didn't have buccal plate but the socket geometry permitted a good prognosis.

Clinical case 1

The following clinical case is of a male patient with 54 years of age that had a trauma on tooth 21. The tooth had an infra bone horizontal fracture with mobility of the coronal part. It had a small periapical asymptomatic lesion.

Treatment options:

1. Extract the tooth, wait 6 weeks to heal and after healing making a bone graft. After 4-6 months place an implant.
2. Extract the tooth and make an immediate bone and soft tissue graft. After 4-6 months of healing place an implant.
3. Extract the tooth, wait 6 weeks and place an implant with simultaneous soft and hard tissue grafting.
4. Extract the tooth and make an immediate bone and soft tissue graft with immediate implant placement.

The proposal made to the patient was to extract the tooth and to place an implant-supported all-ceramic crown. The patient did not have any significant health problems and was a non-smoker. He had good oral hygiene habits. (Fig 1)

After the extraction of the tooth with minimal trauma, it was noted that it had an apical defect. (Fig 2)

The next step was to clean the socket with a curette and analyze the post extraction socket with a probe in order to classify the bony defect that we were facing. Apart from the obvious lack of soft tissues we observed that there was also a loss of the buccal plate. We were facing a combined bone defect, horizontal as well as vertical, with loss of the soft tissues.

The most predictable treatment was immediate delayed implant plus GBR and subepithelial connective tissue grafting. The option of immediate implant placement with GBR and subepithelial connective tissue grafting was made because we were facing a thick gingival biotype, a large width of keratinized gingiva, and a favorable socket morphology. In our opinion we were facing a moderate risk of esthetic achievement. The patient was aware of the risk and signed a consent form. He preferred not to go through two surgeries. (Fig 3)

Access was obtained through a total thickness flap with a vertical releasing incision on tooth 22. An oblique incision up to the concavity between teeth 22 and 23 was used in order to avoid future gingival defects or scars.

On tooth 11 a tunnel⁸ was made (partial thickness flap) to receive a connective tissue graft from the palate that would cover the gingival recession. Because there was enough

¹ Graduated in 2003 from Coimbra's University, Faculty of Medicine, Department of Dentistry, Portugal

remaining bone height beyond the apex of the socket to stabilize an implant, a decision was made to place it immediately.

A SEVEN® 4.20 x 11.5 implant from MIS with an insertion torque of 35Ncm was used. In order to obtain a higher initial stability, the last drill was not used in the surgical protocol. The implant was placed at the level of the cement enamel junction of the adjoining teeth.⁹ (Fig 4)

After the placement of the implant, the next step taken was the placement of the bone graft to correct the bone defect.¹⁰ To achieve that, we used Gen-Os® (porcine cancellous-cortical heterologous bone mix) mixed with BOND BONE® (biphasic calcium sulfate). (Fig 5)

In these types of defects, and because it creates a composite with the granules of bone, BONDBONE® has several main advantages as it enables:

- Not to use a membrane.
- An optimal dimensional stability during and after the surgery.
- Non-interference with the soft tissues graft that was jointly used.
- To shorten the surgery time.
- An increase in the comfort of the surgeon during the surgery.
- Excellent predictability. (Fig 6)

In this particular case, BONDBONE® was not used on its own because we needed a material that would guarantee a slower turn over in order to ensure the bone regeneration; BONDBONE® by itself reabsorbs too quickly and could lead to buccal esthetic problems. However, it is an excellent binder and effective when used as a composite graft. Gen-Os® has granules between 250 µm to 1000µm that enable a very good long term stability which is essential in this type of defects. As it was a combined defect of both soft and hard tissues, a connective tissue graft was also made.

In fact, two types of graft were made: a connective tissue graft to increase the volume of tooth 21 and to cover the root of tooth 11 and a free mucosal graft to obtain primary closure of the socket. In the connective tissue graft we used the left hemi-palate as donor and, with the tunnel technique, we placed the graft in the correct position.

It was stabilized with resorbable suture PGA 6-0 in the locations where it would be impossible to remove and 6-0 poliamide monofil in the locations where it would be possible to remove the sutures. The donor area of the palate was sutured with silk 3-0. (Fig 7)

The free mucosal graft was taken off from

Case 1

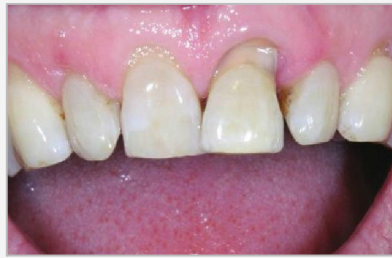

Fig. 1 Initial aspect of the patient with an infra bony fracture on tooth 21.

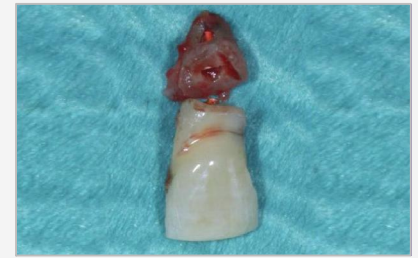

Fig. 2 Tooth 21 with horizontal fracture on the medium 1/3 and an apical defect.

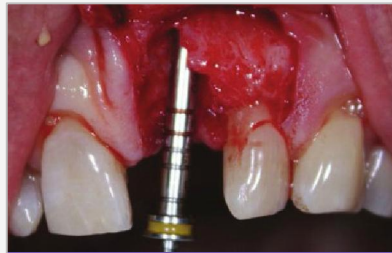

Fig. 3 Combined vertical and horizontal bone defect and deficit of soft tissues.

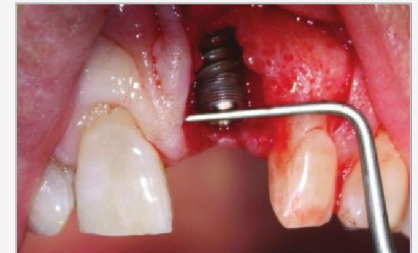

Fig. 4 Immediate placement of implant 4.20x11.5 SEVEN® from MIS.

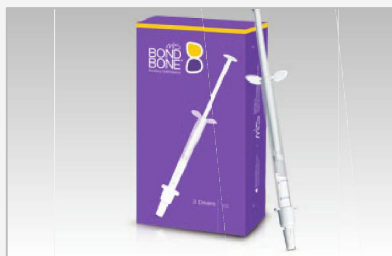

Fig. 5 BOND BONE®

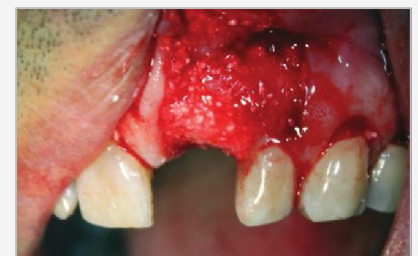

Fig. 6 Appearance of the bone graft stabilized with BOND BONE®.

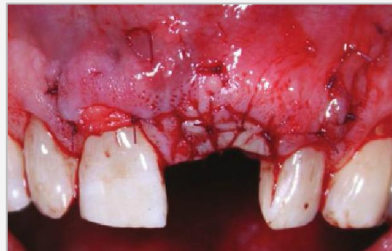

Fig. 7 Frontal view of the soft tissue grafts.

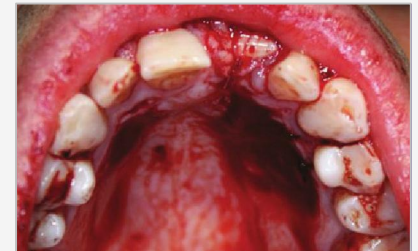

Fig. 8 Sample 2- control area

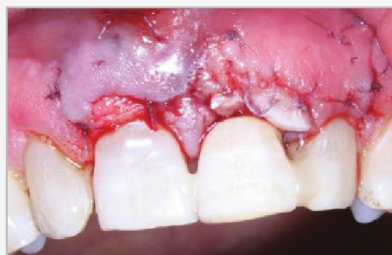

Fig. 9 Provisional restoration with extracted tooth.

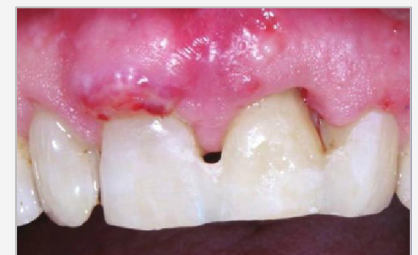

Fig. 10 Appearance on day 15, when sutures were removed.

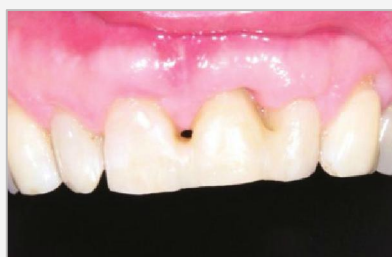

Fig. 11 Adaptation of the temporary crown in order to contour soft tissue and to improve esthetics of the definitive crown.

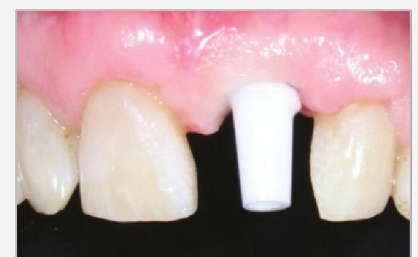

Fig. 12 Selection of the zirconia abutment for the permanent crown.

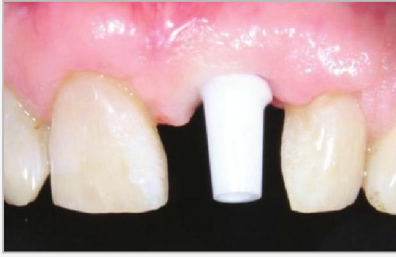


Fig. 12 Selection of the zirconia abutment for the permanent crown.

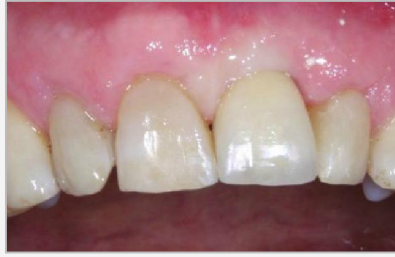

Fig. 13 Color test.

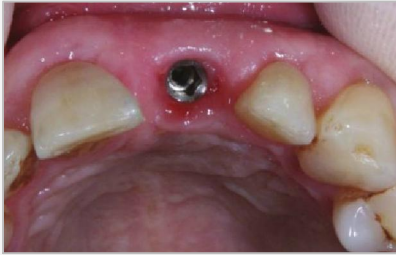

Fig. 14 Occlusal view on the day of the cementation.

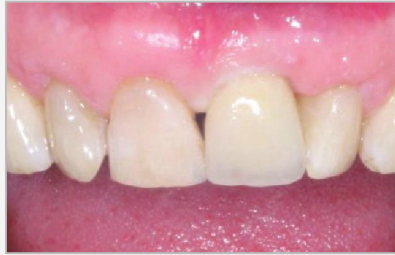

Fig. 15 Cementation of the Zirconzahn® zirconia crown with RelyX Unicem2®.

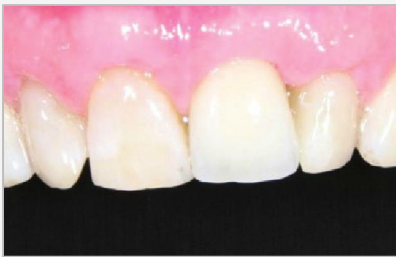

Fig. 16 Appearance 6 weeks after the cementation of the crown.

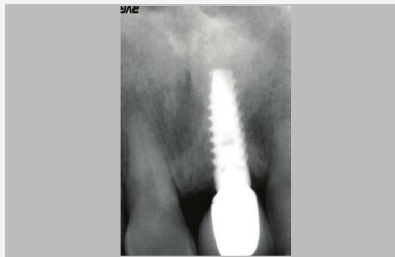


Fig. 16a Rx 2 – Radiological look 6 weeks after the cementation of the crown.

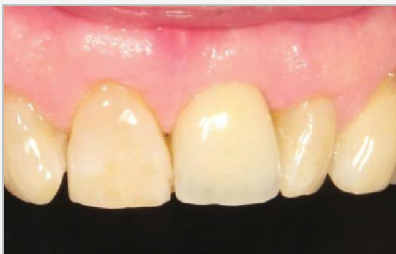

Fig. 17 2 years follow-up.

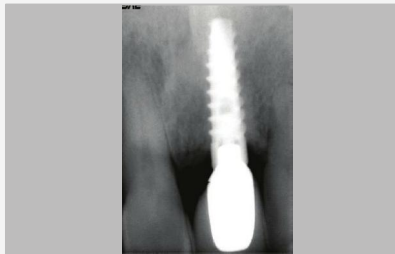

Fig. 17a Sample 2- control area

the right hemi-palate and sutured with 6-0 polyamide monofil only. (Fig 8)

The tooth that had been extracted was used to make a provisional restoration. The root was adapted with a diamond bur and sealed off with flowable composite and it was polished in such a way that would not have retentions that could increase the biofilm accumulation. The crown was fixed with composite to the adjoining teeth. It was placed in such a way that avoids the collapse of the existing¹¹ tissues and that doesn't press grafts in order not to compromise their revascularization. (Fig 9)

The patient was instructed not to brush his teeth 12 to 22 during the healing period and to rinse with 0.12% chlorhexidine for 2 weeks. He took Amoxicillin and Clavulanic Acid (875/125mg) every 12 hours for 8 days, Ibuprofen 600mg every 8 hours for 2 to 3 days and Deflazacorte 30mg once a day for 4 days. An ice pack was also applied on the treated area during the first 3 days. Because Deflazacorte significantly decreases the post-surgical edema it avoids suture dehiscence.

The patient was instructed to avoid physical exertion, rapid head, neck and lip movements. The post-surgical period had no occurrence of bleeding or pain. The edema was minimal. The suture was removed after 15 days and at that point in time it was already possible to observe a revascularization of the soft tissue graft. (Fig 10)

On week 7 composite was added to the temporary crown in order to contour the soft tissues and initiate the modeling of the area where the definitive crown was to be placed. (Fig 11)

On week 12, and after several consecutive adaptations of the temporary crown, the final abutment was selected and a first impression was taken in order to test the zirconia structure. (Fig 12)

An open tray technique with Impregnum® Penta Soft polyether was made. The temporary crown that, up to that moment, was fixed in the adjoining teeth, was replaced by a new provisional polycarbonate crown implant-supported. On week 13 color was tested and occlusion checked. (Fig 13)

The Zirconia Zirconzahn® crown was characterized with Cercon® Kiss ceramics by dental technician Oleksiy Sklyarov from the Cella dental design (Cedlab) laboratory, Portugal. (Fig 14-16)

Clinical case 2

The second clinical case presented is of a female patient with 51 years of age that fractured tooth 11. This tooth had an old porcelain fused to metal crown with a metallic post. The tooth had several fractures and no viability.

Treatment options:

1. Extract the tooth, clean the socket and after a 6 weeks healing period make a bone graft with delayed implant placement.
2. Extract the tooth, clean the socket and make an immediate bone and soft tissue graft with delayed implant placement.
3. Extract the tooth, clean the socket and make an immediate bone and soft tissue graft with immediate implant placement.

The proposal made to the patient was to extract the tooth and place an implant with soft and hard tissue grafting (all in the same surgery) and, following a 4-6 month healing period, to place an allceramic crown. The patient didn't have any significant health problems and was a non-smoker. She had good oral hygiene habits except in that particular area where she wasn't able to brush because the crown moved and inflicted pain. She was aware of the risks of this procedure and signed a consent form. (Fig 1)

After removing the moving crown, several pieces of the root were extracted as well as granulation tissue. The socket was cleaned with a curette and it was noticed that there was no buccal plate. A fistula was also present in the vestibular aspect of the mucosa. There was no active infection because the patient had taken prophylactic antibiotics (amoxicillin + clavulanic acid 875+125mg, 12/12 h during 5 days before surgery). (Fig 2)

The lack of a buccal plate forced the socket to be grafted but, because there wasn't a soft tissue deficit, it wasn't necessary to increase the height of the gingiva. Probably the less risky treatment would have been the immediate delayed implant with guided bone regeneration but the thick biotype⁷, socket morphology and patient compliance and consent made us believe that immediate implant placement only had a moderate risk (instead of a high risk as described by Juozbalys' and Wang's classification⁷). (Fig 3)

Access was obtained through a total thickness flap with a vertical releasing incision distally to tooth 12. An oblique incision up to the concavity between teeth 12 and 13 was used

Case 2

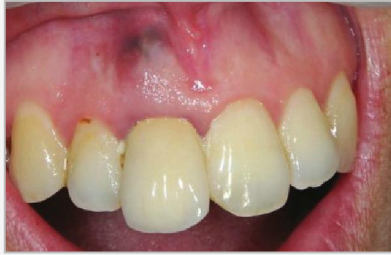

Fig. 1 Initial frontal view of the crown.

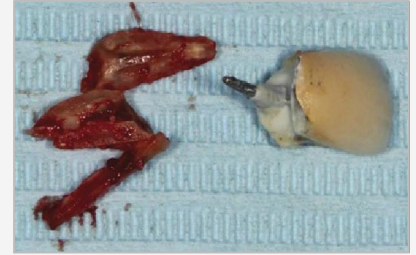


Fig. 2 Porcelain fused to metal crown and the several pieces of the root.

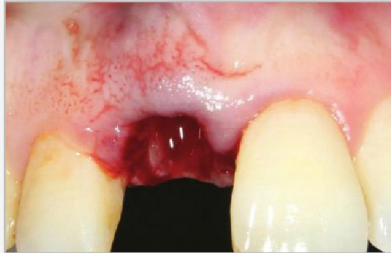

Fig. 3 Aspect after root removal. There is no soft tissue deficit. Frontal view.

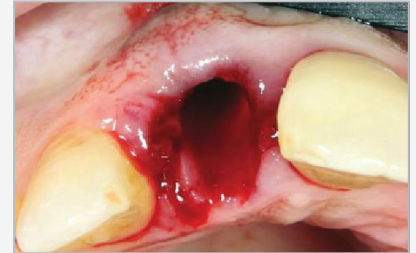

Fig. 3a Aspect after root removal. Occlusal view.

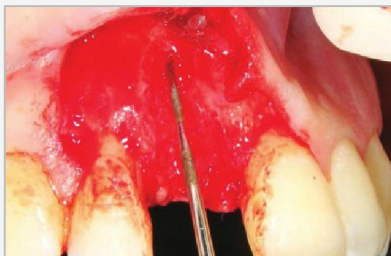

Fig. 4 Loss of the buccal plate.

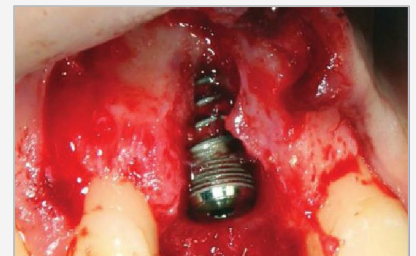

Fig. 5 MIS SEVEN® 4.20x13 implant Front view.

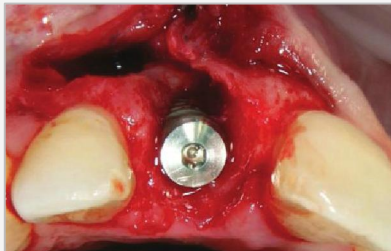

Fig. 6 MIS SEVEN® 4.20x13 implant. Occlusal view.

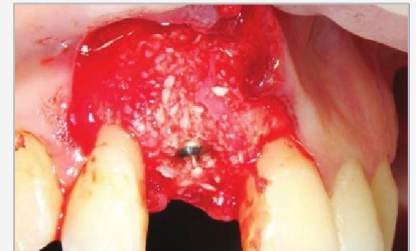

Fig. 7 Gen-Os mixed with BONDBONE®. BONDBONE® was used as a composite.

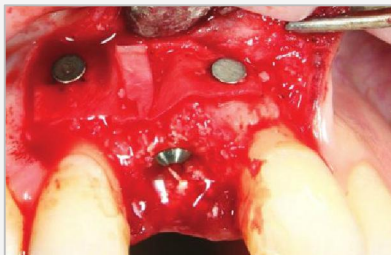


Fig. 8 Mem-Lok fixed with tacks. Excesses of the membrane placed in the fistula region. Front view.

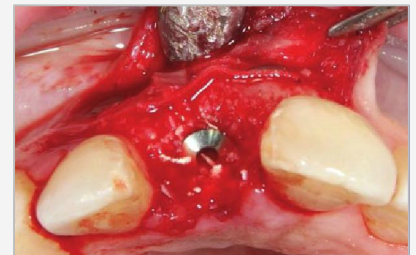


Fig. 9 Mem-Lok fixed with tacks. Excesses of the membrane placed in the fistula region. Occlusal view.

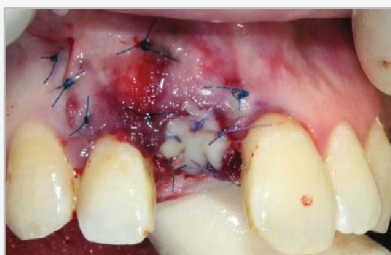

Fig. 10 Free mucosal graft. Front view.

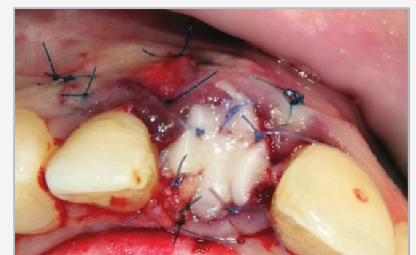

Fig. 11 Free mucosal graft. Occlusal view.

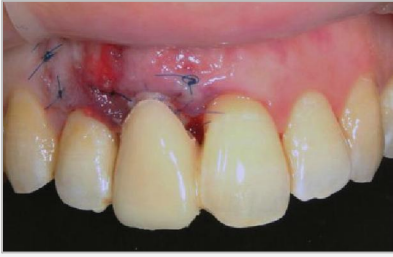

Fig. 12 Provisional fixed restoration.

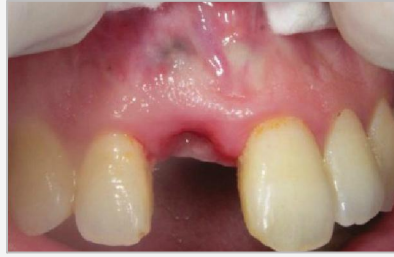

Fig. 13 4 months.

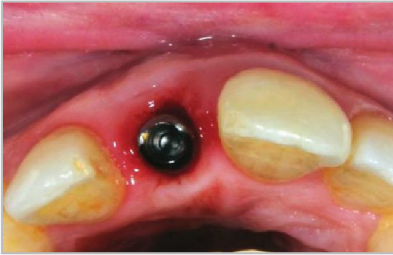

Fig. 14 Results at the time of the impression.

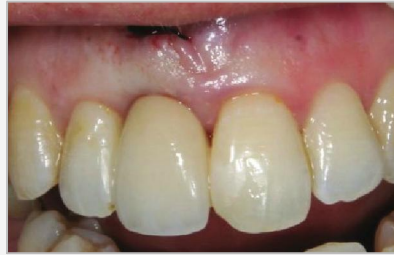

Fig. 15 Color check and tack removal.

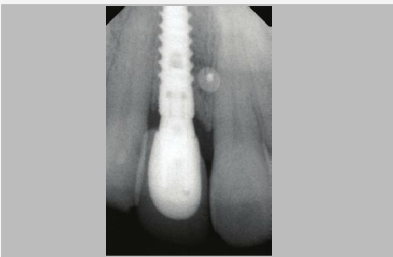

Fig. 15a Rx 1 – Aspect on the day of color and occlusion check.

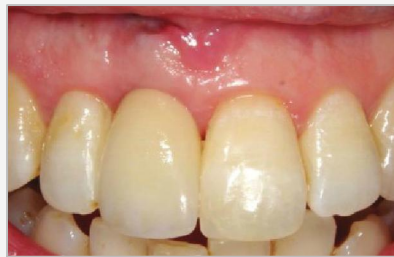

Fig. 16 All-ceramic e.max crown one week after cementation.

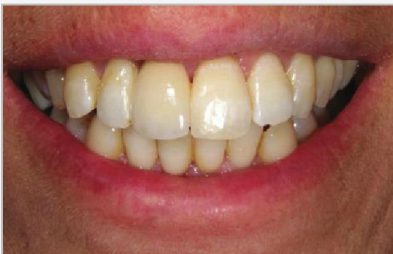

Fig. 17 Patient smile.

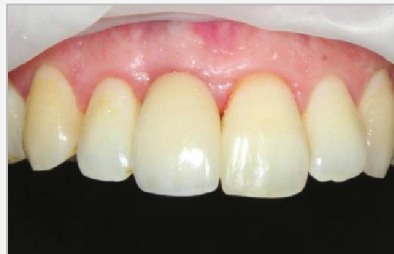

Fig. 18 Ten months follow-up.

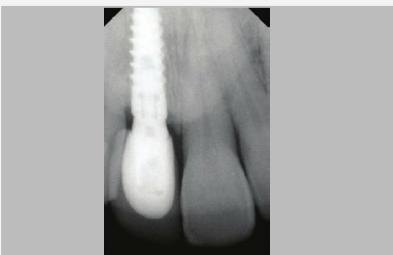


Fig. 18a Rx 2 – 10 Months follow-up.

in order to permit a good access with minimal esthetic problems. (Fig 4)

Apical and surrounding bone allowed immediate implant placement. A MIS SEVEN® 4.20x13 implant was placed with a 45Ncm insertion torque. A good primary stability is necessary in order to avoid implant movements. (Fig 5, 6)

The implant was placed at the level of the cement enamel junction of the adjoining teeth and no angulation was needed.

The gap between the implant and the socket wall was filled with Gen-Os (porcine cancellous-cortical heterologous bone mix) mixed with BONDBONE® (biphasic calcium sulfate) and the buccal aspect of the implant was also covered. (Fig7)

The bone graft was covered with a Mem-Lok® membrane (highly purified Type I Collagen derived from bovine achilles tendon. Biohorizons®) and fixed with tacks.

The excesses that were left from the membrane adaptation were placed above the fixed membrane in the region of the removed fistula in order to prevent resorption due to an eventual membrane exposure (it didn't happen). (Fig 8, 9)

The membrane was only placed in the buccal region because there wasn't enough soft tissue and there was a high risk of membrane exposure. In this case we used a membrane because after desgranulation of the mucosa there were some regions where the mucosa stayed very thin and we also wanted to keep buccal volume.

A free mucosal graft was taken from the palate and placed to close the socket. A very thick graft was used but the periosteum was left intact in the palate. It was sutured with 6-0 PV Monofil non-absorbable interrupted sutures.

In the papilla, internal vertical mattress sutures were used to achieve precise approximation and interrupted sutures in the releasing incision. (Fig 10, 11)

After the procedure, a provisional restoration was made with a polycarbonate crown filled with composite. The provisional crown was fixed to the neighboring teeth and contoured to ensure minimal contact with the surgical site. (Fig 12)

The patient was instructed not to brush her teeth during the early healing period and to rinse with 0.12% chlorhexidine for 15 days.

She took Amoxicillin with Clavulanic Acid (875/125mg) every 12 hours for 8 days,

Ibuprofen 600mg every 8 hours for 2 to 3 days and Deflazacorte 30mg once a day for 4 days. Because Deflazacorte significantly decreases the post-surgical edema it avoids suture dehiscence.

An ice pack was also applied on the treated area during the first 3 days. Patient was instructed to avoid physical exertion and rapid head, neck and lip movements. The post-surgical period had no occurrence of bleeding or pain. The edema was minimal.

After a 4 months healing period an implant access was made with a tissue punch as well as implant-supported restoration in order to contour the soft tissues. (Fig 13, 14)

The definitive impression was performed 5 months after surgery and an all ceramic crown (Ivoclar e.max) was made by dental technician, Isabelle Antunes, Systemodental, Portugal. (Fig 15)

Tacks were removed at the same time we made the color and occlusion check. They were removed with a very small incision in the mucosa and sutured with interrupted silk 4-0 sutures. (Fig 16-18)

Conclusion

Using this technique allowed the treatment time to be shortened by several months and, additionally, ensured a high level of predictability.

It allowed for all the regenerative procedures to be performed in only one surgery, decreasing the morbidity and all the discomfort associated with a surgery.

References


1. Lazzara RJ. Immediate implant placement into extraction sites: Surgical and restorative advantages. *Int J Periodontics Restorative Dent* 1989;9:332-343.
2. Schwartz-Arad D, Chaushu G. Immediate implant placement: a procedure without incisions. *J Periodontol* 1998; 69; 743-750.
3. Kan JY, Rungcharassaeng K, Lozada J. Immediate placement and provisionalization of maxillary anterior single implants; 1-year prospective study. *Int J Oral Maxillofacial Implants* 2003;18:31-39.
4. Araujo MG, Sukekava F, Wennstrom JL, Lindhe J. Ridge alterations following implant placement in fresh extraction sockets: an experimental study in the dog. *J Clin Periodontol* 2005; 32: 645- 652.
5. Araujo MG, Lindhe J. Dimensional ridge alterations

following tooth extraction. An experimental study in the dog. *J Clin Periodontol* 2005; 32: 212-218.

6. Araujo MG, Wennstrom JL, Lindhe J. Modeling of the buccal and lingual bone walls of fresh extraction sites following implant installation. *Clin Oral Implants Res* 2006; 17: 606 – 614.
7. Gintaras Juodzbalys, Horn-Lay Wang. Socket morphology – based treatment for implant esthetics: a pilot study. *The International J of Oral and Maxillofacial Implants* 2010; 25: 970- 978.
8. Salama H, Salama M, Garber D. The Tunnel Technique in the Periodontal Plastic Treatment of Multiple Adjacent Gingival Recession Defects: A Review. *Inside Dentistry* 2008; Volume 4; Issue9.
9. Hammerle CH, Bragger U, Burgin W, Lang NP. The effect of subcrestal placement of the polished surface of ITI implants on marginal soft and hard tissues. *Clin Oral Implants Res* 1996; 7:111-119.
10. Cristopher J. van Kesteren, John Schoolfield, Jason West, Thomas Oates. A prospective randomized clinical study of changes in soft tissue position following immediate and delayed implant placement. *The International J of Oral and Maxillofacial Implants* 2010; 25: 562-570.
11. Tortamano P, Camargo L, Bello- Silva M, Kanashiro L. Immediate implant placement and restoration in the esthetic zone: a prospective study with 18 months of follow-up. *The International J of Oral and Maxillofacial Implants* 2010; 25: 345-350.
12. Santosa R, Martin W, Morton D. Effects of a cementing technique in addition to luting agent on the uniaxial retention force of a single-tooth implant-supported restoration: na in vitro study. *The International J of Oral and Maxillofacial Implants* 2010; 25: 1145-1152.

MIS's Quality System complies with international quality control standards: ISO 13485:2003 - Quality Management System for Medical Devices, ISO 9001: 2008 – Quality Management System and CE Directive for Medical Devices 93/42/EEC. MIS's products are cleared for marketing in the USA and CE approved.

© MIS Corporation. All rights Reserved



www.mis-implants.com

mis[®]

MIS Implants Technologies Ltd.